

# Cheek Volumization and the Nasolabial Fold

Donalds S. Mowlds, M.D.  
Val Lambros, M.D.  
Irvine, Calif.



**Background:** The impression that cheek filling results in longitudinal shortening (“lift”) of the skin and elevation of the nasolabial crease or nasolabial fold has become common within the facial injection community but remains unsubstantiated.

**Methods:** In this study, 77 patients were evaluated before and after injection of the cheeks with a hyaluronic acid filler using a three-dimensional camera system.

**Results:** A constant pattern of skin expansion away from the center of the injection and perpendicular to the surface of the skin was observed. A subgroup of 37 patients without differences in their preinjection and postinjection facial expression were analyzed by direct comparison and failed to demonstrate lateral traction (or “pull”) on the intervening skin from the cheek injection site to the nasolabial crease. Furthermore, there was no photographic difference in the nasolabial fold or nasolabial crease. The only patients who demonstrated photographic improvement of the medial face were those who had filler placed directly in the transition between the lateral nasolabial fold and cheek (nasojugal crease).

**Conclusions:** Filling the cheek with 3 cc of volume does not create traction forces or move the skin between the site of injection and the nasolabial crease. It is likely that expanding the nasojugal crease is the direct visual cue that leads to perceived improvement in the nasolabial fold. (*Plast. Reconstr. Surg.* 141: 1124, 2018.)

In our opinion, the use of volume has been the single greatest improvement in the rehabilitation of the aging face since the face lift. With volume adjustments, facial contours and balance can be altered nonsurgically and safely, as evidenced by the enormous interest in injectable fillers and volumization with surgical procedures.<sup>1</sup> Over the past several years, every area of the face has been injected and augmented by skilled injectors with generally good results if the procedure is performed in moderation. Along the way, certain perceptions related to the effect of fillers have

been noted; particularly, that filling the cheeks seems to improve the nasolabial fold contour.<sup>2-5</sup> A rationalization frequently offered by both patients and clinicians is that adding volume to the cheeks creates a pulling force on the skin that elevates the nasolabial crease or nasolabial fold much as fingers will do when simulating a vertical pull in a mirror.<sup>6-14</sup> Some clinicians think that the effect is so powerful that they no longer inject the nasolabial crease at all.

Given the increasing prevalence of cheek fillers and the availability of three-dimensional photography, it seems reasonable to examine the area more closely. The goal of this study was to see whether cheek filling made visible changes in

*From the Department of Plastic Surgery, University of California, Irvine.*

*Received for publication September 6, 2017; accepted December 5, 2017.*

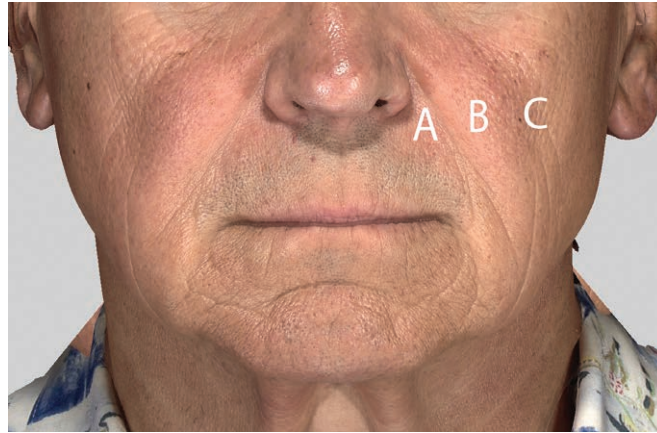
*Presented at the Sixth Annual Summit in Aesthetic Medicine, in Newport Beach, California, June 3 through 4, 2016; the Seventh Annual Summit in Aesthetic Medicine, in Newport Beach, California, May 5 through 6, 2017; the Aesthetic Eyelid and Facial Rejuvenation Course 2017, in Los Angeles, California, July 21 through 22, 2017; the Cosmetic Bootcamp, in Aspen, Colorado, July 7 through 10, 2016; the Cosmetic Bootcamp, in Las Vegas, Nevada, November 3 through 5, 2017; and the 51st Annual Baker Gordon Educational Symposium, in Miami, Florida, February 9 through 11, 2017.*

*Copyright © 2018 by the American Society of Plastic Surgeons*

DOI: 10.1097/PRS.0000000000004341

**Disclosure:** *The authors have no financial interest to declare in relation to the content of this article.*

Supplemental digital content is available for this article. Direct URL citations appear in the text; simply type the URL address into any Web browser to access this content. Clickable links to the material are provided in the HTML text of this article on the *Journal's* website ([www.PRSJournal.com](http://www.PRSJournal.com)).



**Fig. 1.** The medial facial complex contains the nasolabial crease (A), the nasolabial fold (B), and the nasojugal crease (C). The terms are not synonymous.

the nasolabial fold and whether a displacement of skin could explain this difference if it occurred. In Figure 1, the nasolabial crease, nasolabial fold, and nasojugal crease are pictured.

### PATIENTS AND METHODS

Before injecting the patient with cheek filler, a three-dimensional image of the face was taken (Vectra System; Canfield Scientific, Inc., Parsippany, N.J.). The senior author's (V.S.L.) usual practice has been to inject patients with a dilute local anesthetic solution to duplicate the effect of the filler before placing the product itself.<sup>15</sup> This is a familiar concept to patients because it is, in principle, identical to trying on clothes before buying them. It is particularly valuable in the cheeks, as some patients become unpleasantly conscious of their asymmetries when the cheeks are expanded. In addition, some patients realize that they do not like the reality of expanded cheeks as much as the concept. Ideally, these factors would best be discovered before an expensive injection of fillers.

The area to be filled was marked and discussed with the patient. One cc of Voluma hydrates to 1.5 cc of total volume. Therefore, most commonly, 1.5 cc of dilute local anesthetic was injected for each cubic centimeter of product. Because 1 cc of product (Voluma; Allergan, Inc., Dublin, Ireland) is typically used per side, the cheeks are temporarily filled with more than double the amount of intended volume. Therefore, if there is a relationship between cheek filling and improvement of the nasolabial fold, the amplified injection volume should reveal that tendency. One to 3 cc of volume per cheekbone is consistent with the average volume referenced in several publications.<sup>2-5</sup> If the patient approves the "preview," a 25-gauge, 1½-inch blunt cannula is

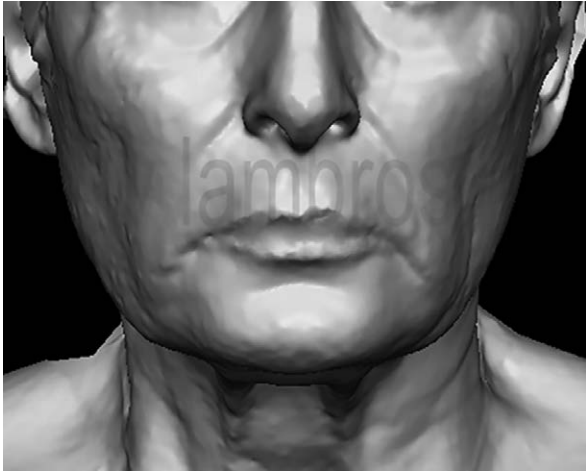
used to place serial depots of filler in the desired areas. Immediately after the injection, another three-dimensional image is taken, registered, and compared with the preinjection image (Figs. 2 and 3). A gif animation was made of the pre- and post-injection images. All patients consented to photographs and publication of cropped images.

Because the human face is in constant motion, it is not easy to reproduce an absolutely stable facial expression. The smallest smile or relaxation of the perioral area can move the face enough to overwhelm the small effects of the cheek fill. To demonstrate the (relatively) pure effect of cheek filling, patients were evaluated for nasolabial fold differences only if their lips, nostril base, or nasolabial crease moved by less than 1 mm between images. Larger differences were invariably from a small smile or other muscular facial expression. Differences of 1 mm or less of cheek skin position were considered moot. The observer should follow points on the face and play the images for some time, as subtleties become visible with repetition.

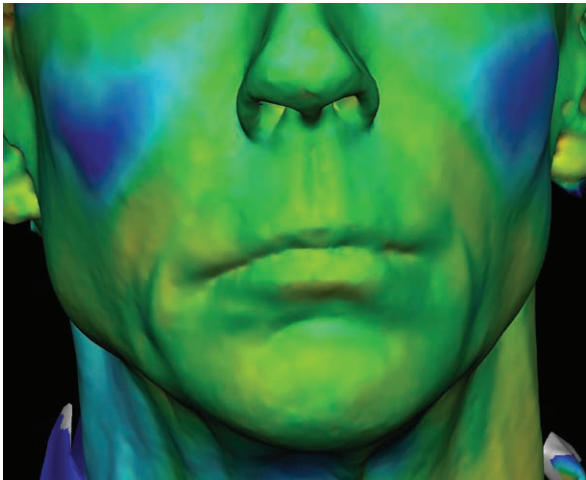
### RESULTS

Cheek expansion following injection was evaluated in 77 patients. Placement of filler resulted in expansion of the skin outward from the center of volume of the injection. This is analogous to dots on an inflating balloon: when seen from above, the dots will spread in all directions. When seen tangentially to the expansion, the dots will move outward, perpendicular to the surface plane of the balloon (Fig. 4). (See Animation, Supplemental Digital Content 1, [hyperlink available in Appendix.](#)) This pattern was reproduced in all 77 patients treated.

Of the 77 patients, 37 patients with stable facial expression were used to determine the

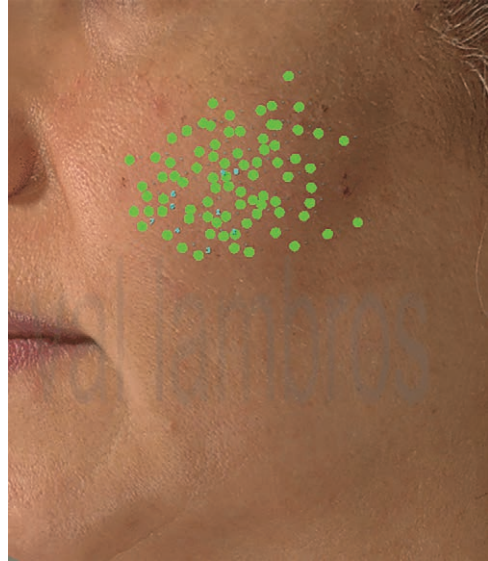

**Fig. 2.** Animated three-dimensional surface images are by far the best way to see the addition of a small amount of volume in the face. One can see the exact location of local anesthetic and 1 cc of Voluma in the cheekbones. (See Animation, Supplemental Digital Content 10A, for corresponding animations, hyperlink available in Appendix 1.)



**Fig. 3.** A color map by distance that shows the effect of filling the cheek. The blue areas have expanded. On the patient's right, the maximum cheek projection from filler is 3.4 mm; on the left, 2.9 mm. (See Animation, Supplemental Digital Content 10, for corresponding animations, hyperlink available in Appendix 1.)

effects of cheek filling on the nasolabial crease and nasolabial fold. By direct comparison, none of these 37 patients with isolated cheek injections showed evidence of lateral traction on the skin between the cheek and nasolabial crease. In addition, there was no difference in the nasolabial crease or fold position following injection. The nasolabial crease did not move unless the lips moved as well. It did not make a difference if filler was injected into the malar or submalar region (Figs. 2 and 3). (See Animations, Supplemental



**Fig. 4.** The essence of this article is seen in these images. The pre-injection and postinjection three-dimensional scans were aligned, and approximately 70 pores and small moles on the face were identified on both images and then animated. What one sees is expansion in three axes, duplicating the effect of inflating a balloon. What one does not see is traction or tissue motion adjacent to the expansion. When seen from anteriorly, the expansion appears as if there is some posterior motion. This is from the projection angle. (See Animation, Supplemental Digital Content 1, for corresponding animations, hyperlink available in Appendix 1.)

**Digital Content 2 through 19, hyperlinks available in Appendix.)**

## DISCUSSION

The word “lift” is used in many different ways and in different contexts. For example, it is used to describe a change in position of skin perpendicular to its plane. It has also been applied to a displacement parallel to the plane of the skin. Either one of these effects could be described as lift, but not both. In this article, we use the term lift to describe a traction force parallel to the plane of the skin as in a face lift or hopeful tug of the cheeks in a mirror. The term “expansion” is given to filling below the surface of the skin, which elevates the skin at right angles to its plane, like a balloon or a breast implant. This is not a semantic argument—these terms could easily be exchanged for others. The question here is whether filling the cheek causes a pulling force on the skin.

The difference in position of the landmarks before and after injection is so small that it is not visible on side-by-side photographs; thus, the pre-injection and postinjection images were assessed through gif animations. Precisely registered sequential images were overlaid, and the top image was



sequentially removed and replaced. This is highly technical and must be performed rigorously; otherwise, the value of the method is lost.

When the process is done well, a large amount of data is presented visually without the need for tables and charts.<sup>16</sup> The three-dimensional camera is a technology that facilitates analysis of this type, as images may be rotated in space for optimal registration.

A pleased patient seems to preclude analysis: the intuitive explanation for the effect of cheek filling on the nasolabial fold is that the filler pulls longitudinally on the skin of the face. Not surprisingly, many patients ask whether this indeed occurs. If true, the nasolabial fold would flatten and the nasolabial crease remain in position but with partial effacement. Neither effect was observed in the patients studied. The essential finding of this study is that filler expansion of the malar and submalar areas of cheek by 3 cc creates an elevation of the skin surface. This elevation *increases* the surface area of the expansion and does not create traction forces on the skin remote from the injection. Because the nature of filling is expansile, the opposite effect occurs: the expansion of an area injected in the subcutaneous plane moves radially outward as seen from above, *not* radially inward as would be expected if skin were being recruited to compensate for a protrusion. If the reader examines his or her face in a mirror and pulls on the cheek at the site of a cheek injection, the amount of cheek displacement necessary to move the nasolabial fold becomes clear. No such change was visible in this study. The idea that skin will recruit longitudinally or “tighten” in response to an expansion perpendicular to the skin is intuitively pleasing but probably does not occur in the face except in extreme circumstances. However, if an object with very high ratio of height to width (e.g., a ping pong ball) rather than a gel-like product were injected, a recruitment effect with skin traction might be observed.

A stereotyped injection of the high cheekbone and zygoma proper can appear good on a younger face, but it makes older, thinning faces appear more cadaveric and gaunt, both innately and by the shadowing of facial hollows seen in daily light. For these reasons, we have a very general rule of thumb: young faces benefit from filling prominences and older faces benefit from filling hollows.

### Why Does Cheek Filler Make the Nasolabial Fold Appear Better?

There is literature that agrees with the patient-reported impression that nasolabial folds and tear troughs may appear better after filling the cheek.<sup>2</sup>

Because the images shown here do not reveal planar motion of the tissues themselves, any perceived nasolabial fold improvement must be from something else.

The face silently expresses a host of expressions, attitudes, states of being, thought, and health. These are ineffably subjective, variable in interpretation, and certainly well beyond the scope of this article. **It may be that the perceived improvement in the fold and crease is simply illusory.** Perhaps expanding the cheek may make the face appear better from a holistic point of view, which may be seen as nasolabial fold improvement.

There seems to be a population in whom the answer is more direct. The only patients whom we considered to show photographic improvement of the nasolabial fold were those who had filler placed in the transition between the lateral nasolabial fold and cheek. This area, usually called the nasojugal crease, frequently hollows in patients who thin as they age and visually separates the cheek from the nasolabial fold. By expanding this area directly, the separation is minimized and thus appears very similar to a cheek that has been pulled (**see Animations, Supplemental Digital Content 15, 17, and 18, hyperlinks available in Appendix**). Note that the nasolabial fold and nasojugal crease skin points on these images did not move along the plane of the face. All movement was expansile and perpendicular to the planar surface of the skin: in and out. **Our conclusion in this group of patients is that the nasolabial fold appears “better” because of direct fill of the nasojugal crease.**

## CONCLUSIONS

By comparing three-dimensional images before and immediately after cheek injection with 1.5 cc of dilute anesthetic and 1 cc of filler per side, a constant pattern of radial skin expansion from the center of the injection and perpendicular to the surface of the skin was observed, analogous to inflating a balloon with dots on its surface. A subgroup of 37 patients without differences in their preinjection and postinjection facial expression were analyzed by direct comparison and did not demonstrate a lateral traction effect of the intervening skin from **the cheek injection site to the nasolabial crease.** Furthermore, there was no photographic difference in the nasolabial fold or nasolabial crease. In a few patients, there was an apparent improvement of the lateral border of the nasolabial fold, but only when it was filled directly. We conclude that direct expansion of the nasojugal crease is a visual cue that leads to

perceived improvement in the nasolabial fold, not filling of the cheek. Other improvement is probably illusory.

*Val Lambros, M.D.*

Department of Plastic Surgery  
University of California, Irvine  
2121 East Coast Highway, Suite 200  
Corona Del Mar, Calif. 92925  
lambrosone@aol.com

## APPENDIX

**Supplemental Digital Content 1A**, <http://links.lww.com/PRS/C694>, **Supplemental Digital Content 1B**, <http://links.lww.com/PRS/C695>, and **Supplemental Digital Content 1C**, <http://links.lww.com/PRS/C696>. Animations demonstrating that the preinjection and postinjection three-dimensional scans were aligned, and approximately 70 pores and small moles in and adjacent to the injected area were identified on both images and then animated. What one sees is expansion in three axes, duplicating the effect of inflating a balloon. What one does not see is traction or tissue motion adjacent to the expansion. When seen from anteriorly, the expansion appears as if there is some posterior motion. This is from the projection angle.

**Supplemental Digital Content 2A**, <http://links.lww.com/PRS/C697>, and **Supplemental Digital Content 2B**, <http://links.lww.com/PRS/C698>. Animation of three-dimensional surface images is by far the best way to see the addition of a small amount of volume in the face. One can see the exact location of local anesthetic and 1 cc of Voluma in the cheekbones. The nasolabial crease remains immobile. There is inconsequential motion of the cheek between the site of injection and the nasolabial fold.

**Supplemental Digital Content 3**, <http://links.lww.com/PRS/C699>. Animation demonstrates the surface image of a patient before and immediately after injection as described. His nasolabial folds arguably appear better but the contour of the fold is unchanged. We ascribe this to direct fill of the nasojugal crease.

**Supplemental Digital Content 4**, <http://links.lww.com/PRS/C700>. Animation demonstrates images taken at approximately 1 month and 4 months after cheek injection. The only visible difference is the smile.

**Supplemental Digital Content 5**, <http://links.lww.com/PRS/C701>. Animation demonstrates before and immediately after injection as described. Note the lack of tissue displacement between the injected area and the nasolabial crease.

**Supplemental Digital Content 6**, <http://links.lww.com/PRS/C702>. Animation demonstrates 4 days after injection as described as well, with 0.5 cc of hyaluronic acid filler in each prejowl sulcus. Note the lack of tissue displacement between the site of injection and the nasolabial crease.

**Supplemental Digital Content 7**, <http://links.lww.com/PRS/C703>. Animation demonstrates injection as described. Note the lack of tissue displacement between the site of injection and the nasolabial crease.

**Supplemental Digital Content 8**, <http://links.lww.com/PRS/C704>. Animation demonstrates injection as described. Note the lack of tissue displacement between the site of injection and the nasolabial crease.

**Supplemental Digital Content 9**, <http://links.lww.com/PRS/C705>. Animation demonstrates injection as described. Note the lack of tissue displacement between the site of injection and the nasolabial crease.

**Supplemental Digital Content 10A**, <http://links.lww.com/PRS/C706>, and **Supplemental Digital Content 10B**, <http://links.lww.com/PRS/C707>. Animations demonstrate injection as described. Note the lack of tissue displacement between the site of injection and the nasolabial crease.

**Supplemental Digital Content 11**, <http://links.lww.com/PRS/C708>. Animation demonstrates injection as described. Note the lack of tissue displacement between the site of injection and the nasolabial crease.

**Supplemental Digital Content 12**, <http://links.lww.com/PRS/C709>. Animation demonstrates 5 days after injection with 1 cc of Voluma in each cheek.

**Supplemental Digital Content 13**, <http://links.lww.com/PRS/C710>. Animation demonstrates injection as described. Note the lack of tissue displacement between the site of injection and the nasolabial crease.

**Supplemental Digital Content 14**, <http://links.lww.com/PRS/C711>. Animation demonstrates injection as described. Note the lack of tissue displacement between the site of injection and the nasolabial crease.

**Supplemental Digital Content 15**, <http://links.lww.com/PRS/C712>. Animation demonstrates a patient who had 8 cc of Voluma injected into his cheeks before and 2 years afterward. One can see how the addition of volume into the nasojugal fold gives the visual impression of the nasolabial fold being improved. (Image from Voluma U.S. Pivotal Study courtesy of Allergan plc.)

**Supplemental Digital Content 16**, <http://links.lww.com/PRS/C713>. Animation demonstrates injection as described. Note the lack of tissue displacement between the site of injection and the nasolabial crease.

**Supplemental Digital Content 17**, <http://links.lww.com/PRS/C714>. Animation demonstrates injection as described. Note the lack of tissue displacement between the site of injection and the nasolabial crease. This patient's nasolabial fold may appear improved, probably because the nasojugal crease was injected directly.

**Supplemental Digital Content 18**, <http://links.lww.com/PRS/C715>. Animation demonstrates injection as described. Note the lack of tissue displacement between the site of injection and the nasolabial crease. This patient's nasolabial fold may appear improved, probably because the nasojugal crease was injected directly.

**Supplemental Digital Content 19**, <http://links.lww.com/PRS/C716>. Animation demonstrates 4 days after injection of the cheeks as described. Note the lack of tissue displacement between the site of injection and the nasolabial crease.

## REFERENCES

1. The American Society for Aesthetic Plastic Surgery. 2016 cosmetic surgery national data bank statistics. Available at: <http://www.surgery.org/sites/default/files/ASAPS-Stats2016.pdf>. Accessed May 11, 2017.
2. Jones D, Murphy DK. Volumizing hyaluronic acid filler for midface volume deficit: 2-year results from a pivotal single-blind randomized controlled study. *Dermatol Surg*. 2013;39:1602–1612.
3. Glaser DA, Kenkel JM, Paradkar-Mitragotri D, Murphy DK, Romagnano L, Drinkwater A. Duration of effect by injection volume and facial subregion for a volumizing hyaluronic acid filler in treating midface volume deficit. *Dermatol Surg*. 2015;41:942–949.
4. Baumann L, Narins RS, Beer K, et al. Volumizing hyaluronic acid filler for midface volume deficit: Results after repeat treatment. *Dermatol Surg*. 2015;41 (Suppl 1):S284–S292.
5. Few J, Cox SE, Paradkar-Mitragotri D, Murphy DK. A multicenter, single-blind randomized, controlled study of a volumizing hyaluronic acid filler for midface volume deficit: Patient-reported outcomes at 2 years. *Aesthet Surg J*. 2015;35:589–599.
6. Tunell A. Everything you need to know about Restylane Lyft. *Harper's BAZAAR*. April 17, 2017. Available at: <http://www.harperbazaar.com/beauty/skin-care/news/al1408/everything-you-need-to-know-about-restylane-lyft/>. Accessed May 14, 2017.
7. Carruthers JD, Carruthers A. Facial sculpting and tissue augmentation. *Dermatol Surg*. 2005;31:1604–1612.
8. Moradi A, Watson J. Current concepts in filler injection. *Facial Plast Surg Clin North Am*. 2015;23:489–494.
9. Wollina U. Facial rejuvenation starts in the midface: Three-dimensional volumetric facial rejuvenation has beneficial effects on nontreated neighboring esthetic units. *J Cosmet Dermatol*. 2016;15:82–88.
10. RealSelf.com. Thinking of Juvederm in nasolabial folds but was suggested Voluma in my cheeks = Advice? Available at: <https://www.realself.com/question/thinking-juvederm-injections-the-nasolabial-folds-suggested-voluma-in-my-cheeks>. Accessed May 14, 2017.
11. RealSelf.com. Will Juvederm in cheeks fix these nasolabial folds? Available at: <https://www.realself.com/question/uk-juvederm-in-cheeks-fix-nasolabial-folds>. Accessed May 14, 2017.
12. RealSelf.com. Did filler in the cheeks worsen nasolabial folds? Available at: <https://www.realself.com/question/filler-cheeks-worsen-nasolabial-folds>. Accessed May 14, 2017.
13. RealSelf.com. Juvederm injected in the high cheekbone, will it lift up the face? Available at: <https://www.realself.com/question/west-palm-beach-fl-juvederm-in-cheekbones>. Accessed May 14, 2017.
14. RealSelf.com. Where to fill: Cheeks to lift nasolabial folds or just nasolabial folds? Available at: <https://www.realself.com/question/connecticut-ct-fill-cheeks-lift-nasolabial-folds-nasolabial-folds>. Accessed May 14, 2017.
15. Lambros V. A technique for filling the temples with highly diluted hyaluronic acid: The “dilution solution”. *Aesthet Surg J*. 2011;31:89–94.
16. Lambros V. Observations on periorbital and midface aging. *Plast Reconstr Surg*. 2007;120:1367–1376; discussion 1377.